Date: 06/12/2024 **Seen By:** Dr Michael L Gellman

Facility Name: Peachtree Wellness Center **Provider NPI:** 1255368916
Facility Address: 1447 Peachtree Street, Atlanta, GA, 30309. Ph - (404) 475-0386 **Provider EIN:** 582542328
Patient Name: IMONI CHAPMAN **Gender:** F **Date Of Birth:** 05/03/2001

Notes:

INTAKE

ACCIDENT INFORMATION

Date Of Accident 06/06/2024
I was a driver when accident happened
There were no witnesses
I was struck from: Front
Approximate speed 0
Other car speed 20
I was not knocked unconscious
Police was notified
This is how I felt during the accident Immediate knee pain
This is how I felt immediately after the accident Knee pain
This is how I felt later that day after the accident Neck
This is how I felt next day after the accident Back and neck

INTAKE

POST-INJURY INFORMATION

Have not seen any other doctor(s)

SUBJECTIVE

Changes in Health since last visit: NA
I did something to make my condition worse: No
Initial visit
**Neck pain (Left side)
Pain level: 8/10
Patient states pain frequency 50-75%
Patient Reports the pain is; since last visit since last visit
Patient describes pain as: Sharp, Ache
Mode of Onset: Traumatic
**Lower Back Pain (Centralized)
Pain level: 7 /10
Patient states pain frequency 50-75%
Patient Reports the pain is; since last visit since last visit
Patient describes pain as: Dull, Ache
Mode of Onset: Traumatic
**Mid Back Pain (Bilateral)
Pain level: 7 /10
Patient states pain frequency 50-75%
Patient Reports the pain is; since last visit since last visit
Patient describes pain as: Dull, Ache
Mode of Onset: Traumatic
** Shoulder (Left side)

Pain level: 7/10
Patient states pain frequency 50-75%
Patient Reports the pain is; since last visit since last visit
Patient describes pain as: Dull, Ache
Mode of Onset: Traumatic
** Knee (Bilateral)
Pain level: 5/10
Patient states pain frequency 50-75%
Patient Reports the pain is; since last visit since last visit
Patient describes pain as: Dull, Ache
Doctor's Notes: Pt is head on collision and presents with above complaints after car accident.

OBJECTIVE

CERVICAL ROM: Decreased
C/S Pain: Flexion, Extension, Left Lateral Flex, Right Lateral Flex, Left Rotation, Right Rotation
LUMBAR ROM: Decreased
L/S Pain: Flexion, Extension, Left Lateral Flex, Right Lateral Flex
Upper Body ROM: Shoulder:Left, Decreased, Pain: Yes
POSTURE: FHP
Cervical Tests
Cervical Compression: Left, Right
Cervical Distraction: Left, Right
Max Foraminal Compression : Left, Right
Shoulder Depression: Left, Right
O'Donoghue Test: Left, Right
Lumbar Tests
Bechterew: Left, Right
Kemps: Left, Right
Lasegue: Left, Right
Faber: Left, Right
Valsalva: Left, Right
SLR: Left, Right
Milgrams: Left, Right
Drop Arm: Negative
Adsons: Negative
Posterior Apprehension: Left
Anterior Apprehension: Left
Speeds: Negative
Dawbarn: Negative
Yergason: Left
Edens: Left
Knee Test
Mc Murray : Left, Right
Patella Grinding : Left, Right
Motion Palpation Restriction: Upper Cervical Spine, Lower Cervical Spine, Upper Thoracic Spine, Mid Thoracic Spine, Lower Lumbar Spine

Upper Body Hypertonicity

Upper Body: Suboccipitals- Bilateral Paraspinals- Left Trapezius- Left Levator scapula- Left Rhomboids- Left

Lower Body Hypertonicity

Lower Body: QL-, Bilateral, Glutes- , Bilateral, Piriformis-, Bilateral

ASSESSMENT

Phase of care: One: Acute pain control
Phase of care: Two: Corrective
The patient has reached MMI: No
Prognosis: Fair (complicated case with improvement expected)

General: Patient complains of ADL's affected due to ongoing pain
Cervical: Patient reports neck pain in extension while gargling
Lumbar: Patient reports problems and difficulty bending and kneeling due to pain. Also, difficult to arise from that position
Knee: Patient reports problems and difficulty bending and kneeling due to pain. Also, difficult to arise from that position
Shoulder: Patient reports being able to lift a gallon of milk or wash hair with less pain than previously

PLAN

Phase Of Care

PASSIVE CARE GOALS (Day 1-30) Anatomical Rest, Reduce muscle spasm, Reduce Inflammation, Alleviate Pain
ACTIVE CARE GOALS (Day 31 to end of treatment) Increase pain free range of motion, Minimize Deconditioning
REHABILITATION (Day 31 to end of treatment) Restore strength and endurance
LIFESTYLE CHANGES Modify social and recreational activities

Treatment Prescription

Diversified
Flexion Distraction
CHIRO MANIPULATION Cervical Spine, Thoracic Spine, Lumbar Spine, Sacrum/Ilium
DIVERSIFIED/ACTIVATOR C1, C2, C3, C4, C5, C6, C7, L3, L4, L5, Right SI

Physical Medicine

MECHANICAL TRACTION Lumbar Spine
Lumbar DTS protocol 40 sec hold/ 20 sec rest / 28 min
HEAT/COLD Lumbar Spine
ELECTRIC MUSCLE STIMULATION Cervical Spine, Lumbar Spine, Thoracic Spine, Extraspinal
OTHER ELECTRIC MUSCLE STIMULATION: shoulders/knees
Manual Therapy: Manual therapy techiques consisting of soft tissue manipulation. The goals are to modulate pain, increase joint range of motion, and reduce or eliminate soft tissue swelling, inflammation, noncontractile tissue extensibility. The manual therapy has been performed due to limited range of motion, muscle spasm, pain, scar tissue, soft tissue swelling, inflammation and/or restriction.
Cervical DTS protocol 40 sec hold/ 20 sec rest / 28 min
Interferential muscle Stimulation: Interferential muscle Stimulation was performed to decrease pain, facilitate healing of inflammed and injured musculoskeletal tissue, increase mobility/range of motion, reduce soft tissue and joint Stress, restore normal muscle tone and reduce muscle spasm. This was performed for 30 minutes with a pulse rate of 1-150Hz.
EMS: Cervical, Thoracic, Lumbar, Paraspinals, Left Shoulder, Left knee
Diversified Spinal CMT
Extremity CMT
Extremity CMT to the: Scapula/Shoulder, Knee
Stretching to Improve Flexibility and ROM: Passive Stretching
Passive Stretching to: Cervical, Lumbar Spine
Rehab Exercises: C/S to improve, C/S Flexibility, C/S Strength, C/S Stability, T/S to improve, T/S Flexibility, T/S Strength, T/S Stability, L/S to improve, L/S Flexibility, L/S Strength, L/S Stability

Muscle Findings

Findings: Inflammation, Muscle spasm(s), Pain, Tightness/Tautness
Location:Bilateral
Spine: Cervical Extensors, Trapezius
Upper Extremity: Thoracic extensor, Pectoralis major/minor, Rhomboids, Levator scapulae
Lower Extremity: Lumbar Extensor, Quadratus Lumborum, Piriformis

Therapeutic Exercises

Rehab: Neck sprain/strain exercises, Upper back exercises, Rhomboid exercises, Mckenzie lower back exercises, Neck extension exercises/stretches, Lumbar herniated disc exercises, Low back pain exercises, Piriformis and Glute exercises, Rotator Cuff exercises

Treatment Plan

Your recommended Action Plan is based on: Your Age, MRI Report, Number of Exam Abnormalities, Your History and Physical Examination, Posture / Range of Motion Abnormalities, Number of Subluxations of Spinal Vertebrae, Subluxation-Acute(6-10 weeks/14-24 visits), Neck Pain(4-6 weeks/10-18 visits), Low Back Pain(4-6 weeks/10-18 visits), Sprain/Strain - Moderate(8-16 weeks/24-32 visits), Muscle/Fascia Inflammation(6-10 weeks/14-22 visits)

My specific recommendation: My specific recommendations in your particular case are based on your individual exam findings and the current utilization guidelines for chiropractic care. Please understand that healing and pain relief is a matter of time. We are reshaping the spinal structures and musculature around the spine(think of braces). PHASES OF CARE 1.Intensive Care: 2-3x week for 3 weeks. 2.Reconstructive Care: 2x week for 8 weeks 3.Retainer Care: 2x month for 2 months 4.Maintenance Care: 1x a month for life to maintain a healthy nervous system.
Doctor Recommended Action Plan: Spinal Adjustments, Extremity Adjustments, Therapeutic Exercise, Electrical Stimulation, Hot Pack, Cold Pack, Vibration Therapy, LED Laser Therapy
Home Instructions: Heat
Patient Response to Treatment: Without Incident
Patient Reports: Relief
3x , Frequency per week for 1 month
2x , Frequency per week for 2 months
ESTIMATED TOTAL TREATMENT LENGTH IS 90 DAYS
ESTIMATED RE-VAL PERIOD IS 60 DAYS

Electronically Signed By: Dr Michael L Gellman

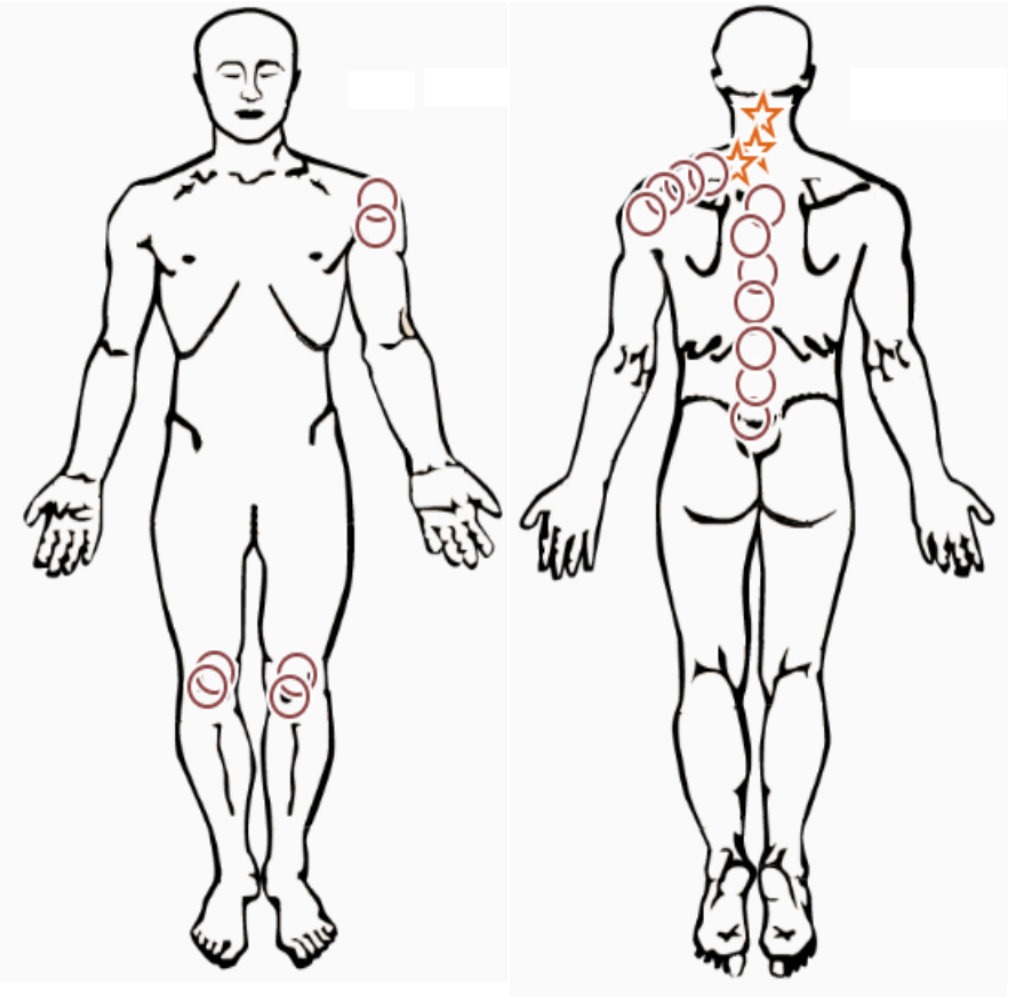

- **Ache / Dull**
- **Sharp / Stabbing**
- **Numb / Tingling**
- **Pins & Needles**
- **Burning**
- **Throbbing**
- **Cramping**
- **Radiating**
- **Other Pains**

Date: 06/17/2024 **Seen By:** Dr Michael L Gellman

Facility Name: Peachtree Wellness Center **Provider NPI:** 1255368916
Facility Address: 1447 Peachtree Street, Atlanta, GA, 30309. Ph - (404) 475-0386 **Provider EIN:** 582542328
Patient Name: IMONI CHAPMAN **Gender:** F **Date Of Birth:** 05/03/2001

Notes:

SUBJECTIVE

My overall condition is: Same
Changes in Health since last visit: NA
I did something to make my condition worse: No
**Neck pain (Left side)
Pain level: 6/10
Patient states pain frequency 50-75%
Patient Reports the pain is; better since last visit
Patient describes pain as: Sharp, Ache
Mode of Onset: Traumatic
**Lower Back Pain (Centralized)
Pain level: 7 /10
Patient states pain frequency 50-75%
Patient Reports the pain is; unchanged since last visit
Patient describes pain as: Dull, Ache
Mode of Onset: Traumatic
**Mid Back Pain (Bilateral)
Pain level: 7 /10
Patient states pain frequency 50-75%
Patient Reports the pain is; unchanged since last visit
Patient describes pain as: Dull, Ache
Mode of Onset: Traumatic
** Shoulder (Left side)
Pain level: 7/10
Patient states pain frequency 50-75%
Patient Reports the pain is; unchanged since last visit
Patient describes pain as: Dull, Ache
Mode of Onset: Traumatic
** Knee (Bilateral)
Pain level: 5/10
Patient states pain frequency 50-75%
Patient Reports the pain is; unchanged since last visit
Patient describes pain as: Dull, Ache
Doctor's Notes: Pt is head on collision and presents with above complaints after car accident.

OBJECTIVE

POSTURE: FHP, C/S Rot Right
Motion Palpation Restriction: Upper Cervical Spine, Lower Cervical Spine, Upper Thoracic Spine, Mid Thoracic Spine, Lower Lumbar Spine, Left Sacro-Iliac Joint

Upper Body Hypertonicity

Upper Body: Paraspinals- Bilateral Trapezius- Bilateral Levator scapula- Left Rhomboids- Bilateral

Lower Body Hypertonicity

Lower Body: QL-, Bilateral

ASSESSMENT

Phase of care: One: Acute pain control

Phase of care: Two: Corrective
The patient has reached MMI: No
Prognosis: Fair (complicated case with improvement expected)
General: Patient complains of ADL's affected due to ongoing pain
Cervical: Patient reports neck pain in extension while gargling
Lumbar: Patient reports problems and difficulty bending and kneeling due to pain. Also, difficult to arise from that position
Knee: Patient reports problems and difficulty bending and kneeling due to pain. Also, difficult to arise from that position
Shoulder: Patient reports being able to lift a gallon of milk or wash hair with less pain than previously

PLAN

Phase Of Care

PASSIVE CARE GOALS (Day 1-30) Anatomical Rest, Reduce muscle spasm, Reduce Inflammation, Alleviate Pain
ACTIVE CARE GOALS (Day 31 to end of treatment) Increase pain free range of motion, Minimize Deconditioning
REHABILITATION (Day 31 to end of treatment) Restore strength and endurance
LIFESTYLE CHANGES Modify social and recreational activities

Treatment Prescription

Diversified
Flexion Distraction
CHIRO MANIPULATION Cervical Spine, Thoracic Spine, Lumbar Spine, Sacrum/Ilium
DIVERSIFIED/ACTIVATOR C1, C2, C3, C4, C5, C6, C7, L3, L4, L5, Right SI

Physical Medicine

MECHANICAL TRACTION Lumbar Spine
Lumbar DTS protocol 40 sec hold/ 20 sec rest / 28 min
HEAT/COLD Lumbar Spine
ELECTRIC MUSCLE STIMULATION Cervical Spine, Lumbar Spine, Thoracic Spine, Extraspinal
OTHER ELECTRIC MUSCLE STIMULATION: shoulders/knees
Manual Therapy: Manual therapy techiques consisting of soft tissue manipulation. The goals are to modulate pain, increase joint range of motion, and reduce or eliminate soft tissue swelling, inflammation, noncontractile tissue extensibility. The manual therapy has been performed due to limited range of motion, muscle spasm, pain, scar tissue, soft tissue swelling, inflammation and/or restriction.
Cervical DTS protocol 40 sec hold/ 20 sec rest / 28 min
Interferential muscle Stimulation: Interferential muscle Stimulation was performed to decrease pain, facilitate healing of inflammed and injured musculoskeletal tissue, increase mobility/range of motion, reduce soft tissue and joint Stress, restore normal muscle tone and reduce muscle spasm. This was performed for 30 minutes with a pulse rate of 1-150Hz.
EMS: Cervical, Thoracic, Lumbar, Paraspinals, Left Shoulder, Left knee
Diversified Spinal CMT
Extremity CMT
Extremity CMT to the: Scapula/Shoulder, Knee
Stretching to Improve Flexibility and ROM: Passive Stretching
Passive Stretching to: Cervical, Lumbar Spine
Rehab Exercises: C/S to improve, C/S Flexibility, C/S Strength, C/S Stability, T/S to improve, T/S Flexibility, T/S Strength, T/S Stability, L/S to improve, L/S Flexibility, L/S Strength, L/S Stability

Muscle Findings

Findings: Inflammation, Muscle spasm(s), Pain, Tightness/Tautness
Location:Bilateral
Spine: Cervical Extensors, Trapezius
Upper Extremity: Thoracic extensor, Pectoralis major/minor, Rhomboids, Levator scapulae
Lower Extremity: Lumbar Extensor, Quadratus Lumborum, Piriformis

Therapeutic Exercises

Rehab: Neck sprain/strain exercises, Upper back exercises, Rhomboid exercises, Mckenzie lower back exercises, Neck extension exercises/stretches, Lumbar herniated disc exercises, Low back pain exercises, Piriformis and Glute exercises, Rotator Cuff exercises

Treatment Plan

Your recommended Action Plan is based on: Your Age, MRI Report, Number of Exam Abnormalities, Your History and Physical Examination, Posture / Range of Motion Abnormalities, Number of Subluxations of Spinal Vertebrae, Subluxation-Acute(6-10 weeks/14-24 visits), Neck Pain(4-6 weeks/10-18 visits), Low Back Pain(4-6 weeks/10-18 visits), Sprain/Strain - Moderate(8-16 weeks/24-32 visits), Muscle/Fascia Inflammation(6-10 weeks/14-22 visits)
My specific recommendation: My specific recommendations in your particular case are based on your individual exam findings and the current utilization guidelines for chiropractic care. Please understand that healing and pain relief is a matter of time. We are reshaping the spinal structures and musculature around the spine(think of braces). PHASES OF CARE 1.Intensive Care: 2-3x week for 3 weeks. 2.Reconstructive Care: 2x week for 8 weeks 3.Retainer Care: 2x month for 2 months 4.Maintenance Care: 1x a month for life to maintain a healthy nervous system.
Doctor Recommended Action Plan: Spinal Adjustments, Extremity Adjustments, Therapeutic Exercise, Electrical Stimulation, Hot Pack, Cold Pack, Vibration Therapy, LED Laser Therapy
Home Instructions: Heat
Patient Response to Treatment: Without Incident
Patient Reports: Relief
3x , Frequency per week for 1 month
2x , Frequency per week for 2 months
ESTIMATED TOTAL TREATMENT LENGTH IS 90 DAYS
ESTIMATED RE-VAL PERIOD IS 60 DAYS

Electronically Signed By: Dr Michael L Gellman

Date: 06/20/2024 **Seen By:** Dr Michael L Gellman

Facility Name: Peachtree Wellness Center **Provider NPI:** 1255368916
Facility Address: 1447 Peachtree Street, Atlanta, GA, 30309. Ph - (404) 475-0386 **Provider EIN:** 582542328
Patient Name: IMONI CHAPMAN **Gender:** F **Date Of Birth:** 05/03/2001

Notes:

SUBJECTIVE

My overall condition is: Same
Changes in Health since last visit: NA
I did something to make my condition worse: No
**Neck pain (Left side)
Pain level: 4/10
Patient states pain frequency 0-25%
Patient Reports the pain is; better since last visit
Patient describes pain as: Ache
Mode of Onset: Traumatic
**Lower Back Pain (Centralized)
Pain level: 7 /10
Patient states pain frequency 50-75%
Patient Reports the pain is; unchanged since last visit
Patient describes pain as: Dull, Ache
Mode of Onset: Traumatic, Insidious
**Mid Back Pain (Bilateral)
Pain level: 7 /10
Patient states pain frequency 50-75%
Patient Reports the pain is; unchanged since last visit
Patient describes pain as: Dull, Ache
Mode of Onset: Traumatic
** Shoulder (Left side)
Pain level: 4/10
Patient states pain frequency 0-25%
Patient Reports the pain is; unchanged since last visit
Patient describes pain as: Dull, Ache
Mode of Onset: Traumatic
** Knee (Bilateral)
Pain level: 0/10
Patient states pain frequency 0-25%
Patient Reports the pain is; better since last visit
Patient describes pain as: Dull, Ache
Doctor's Notes: Pt is head on collision and presents with above complaints after car accident.

OBJECTIVE

POSTURE: FHP, C/S Rot Right
Motion Palpation Restriction: Upper Cervical Spine, Lower Cervical Spine, Upper Thoracic Spine, Mid Thoracic Spine, Lower Lumbar Spine, Left Sacro-Iliac Joint

Upper Body Hypertonicity

Upper Body: Paraspinals- Bilateral Trapezius- Bilateral Levator scapula- Left Rhomboids- Bilateral

Lower Body Hypertonicity

Lower Body: QL-, Bilateral

ASSESSMENT

Phase of care: One: Acute pain control

Phase of care: Two: Corrective
The patient has reached MMI: No
Prognosis: Fair (complicated case with improvement expected)
General: Patient complains of ADL's affected due to ongoing pain
Cervical: Patient reports neck pain in extension while gargling
Lumbar: Patient reports problems and difficulty bending and kneeling due to pain. Also, difficult to arise from that position
Knee: Patient reports problems and difficulty bending and kneeling due to pain. Also, difficult to arise from that position
Shoulder: Patient reports being able to lift a gallon of milk or wash hair with less pain than previously

PLAN

Phase Of Care

PASSIVE CARE GOALS (Day 1-30) Anatomical Rest, Reduce muscle spasm, Reduce Inflammation, Alleviate Pain
ACTIVE CARE GOALS (Day 31 to end of treatment) Increase pain free range of motion, Minimize Deconditioning
REHABILITATION (Day 31 to end of treatment) Restore strength and endurance
LIFESTYLE CHANGES Modify social and recreational activities

Treatment Prescription

Diversified
Flexion Distraction
CHIRO MANIPULATION Cervical Spine, Thoracic Spine, Lumbar Spine, Sacrum/Ilium
DIVERSIFIED/ACTIVATOR C1, C2, C3, C4, C5, C6, C7, L3, L4, L5, Right SI

Physical Medicine

MECHANICAL TRACTION Lumbar Spine
Lumbar DTS protocol 40 sec hold/ 20 sec rest / 28 min
HEAT/COLD Lumbar Spine
ELECTRIC MUSCLE STIMULATION Cervical Spine, Lumbar Spine, Thoracic Spine, Extraspinal
OTHER ELECTRIC MUSCLE STIMULATION: shoulders/knees
Manual Therapy: Manual therapy techiques consisting of soft tissue manipulation. The goals are to modulate pain, increase joint range of motion, and reduce or eliminate soft tissue swelling, inflammation, noncontractile tissue extensibility. The manual therapy has been performed due to limited range of motion, muscle spasm, pain, scar tissue, soft tissue swelling, inflammation and/or restriction.
Cervical DTS protocol 40 sec hold/ 20 sec rest / 28 min
Interferential muscle Stimulation: Interferential muscle Stimulation was performed to decrease pain, facilitate healing of inflammed and injured musculoskeletal tissue, increase mobility/range of motion, reduce soft tissue and joint Stress, restore normal muscle tone and reduce muscle spasm. This was performed for 30 minutes with a pulse rate of 1-150Hz.
EMS: Cervical, Thoracic, Lumbar, Paraspinals, Left Shoulder, Left knee
Diversified Spinal CMT
Extremity CMT
Extremity CMT to the: Scapula/Shoulder, Knee
Stretching to Improve Flexibility and ROM: Passive Stretching
Passive Stretching to: Cervical, Lumbar Spine
Rehab Exercises: C/S to improve, C/S Flexibility, C/S Strength, C/S Stability, T/S to improve, T/S Flexibility, T/S Strength, T/S Stability, L/S to improve, L/S Flexibility, L/S Strength, L/S Stability

Muscle Findings

Findings: Inflammation, Muscle spasm(s), Pain, Tightness/Tautness
Location:Bilateral
Spine: Cervical Extensors, Trapezius
Upper Extremity: Thoracic extensor, Pectoralis major/minor, Rhomboids, Levator scapulae
Lower Extremity: Lumbar Extensor, Quadratus Lumborum, Piriformis

Therapeutic Exercises

Rehab: Neck sprain/strain exercises, Upper back exercises, Rhomboid exercises, Mckenzie lower back exercises, Neck extension exercises/stretches, Lumbar herniated disc exercises, Low back pain exercises, Piriformis and Glute exercises, Rotator Cuff exercises

Treatment Plan

Your recommended Action Plan is based on: Your Age, MRI Report, Number of Exam Abnormalities, Your History and Physical Examination, Posture / Range of Motion Abnormalities, Number of Subluxations of Spinal Vertebrae, Subluxation-Acute(6-10 weeks/14-24 visits), Neck Pain(4-6 weeks/10-18 visits), Low Back Pain(4-6 weeks/10-18 visits), Sprain/Strain - Moderate(8-16 weeks/24-32 visits), Muscle/Fascia Inflammation(6-10 weeks/14-22 visits)
My specific recommendation: My specific recommendations in your particular case are based on your individual exam findings and the current utilization guidelines for chiropractic care. Please understand that healing and pain relief is a matter of time. We are reshaping the spinal structures and musculature around the spine(think of braces). PHASES OF CARE 1.Intensive Care: 2-3x week for 3 weeks. 2.Reconstructive Care: 2x week for 8 weeks 3.Retainer Care: 2x month for 2 months 4.Maintenance Care: 1x a month for life to maintain a healthy nervous system.
Doctor Recommended Action Plan: Spinal Adjustments, Extremity Adjustments, Therapeutic Exercise, Electrical Stimulation, Hot Pack, Cold Pack, Vibration Therapy, LED Laser Therapy
Home Instructions: Heat
Patient Response to Treatment: Without Incident
Patient Reports: Relief
3x , Frequency per week for 1 month
2x , Frequency per week for 2 months
ESTIMATED TOTAL TREATMENT LENGTH IS 90 DAYS
ESTIMATED RE-VAL PERIOD IS 60 DAYS

Electronically Signed By: Dr Michael L Gellman

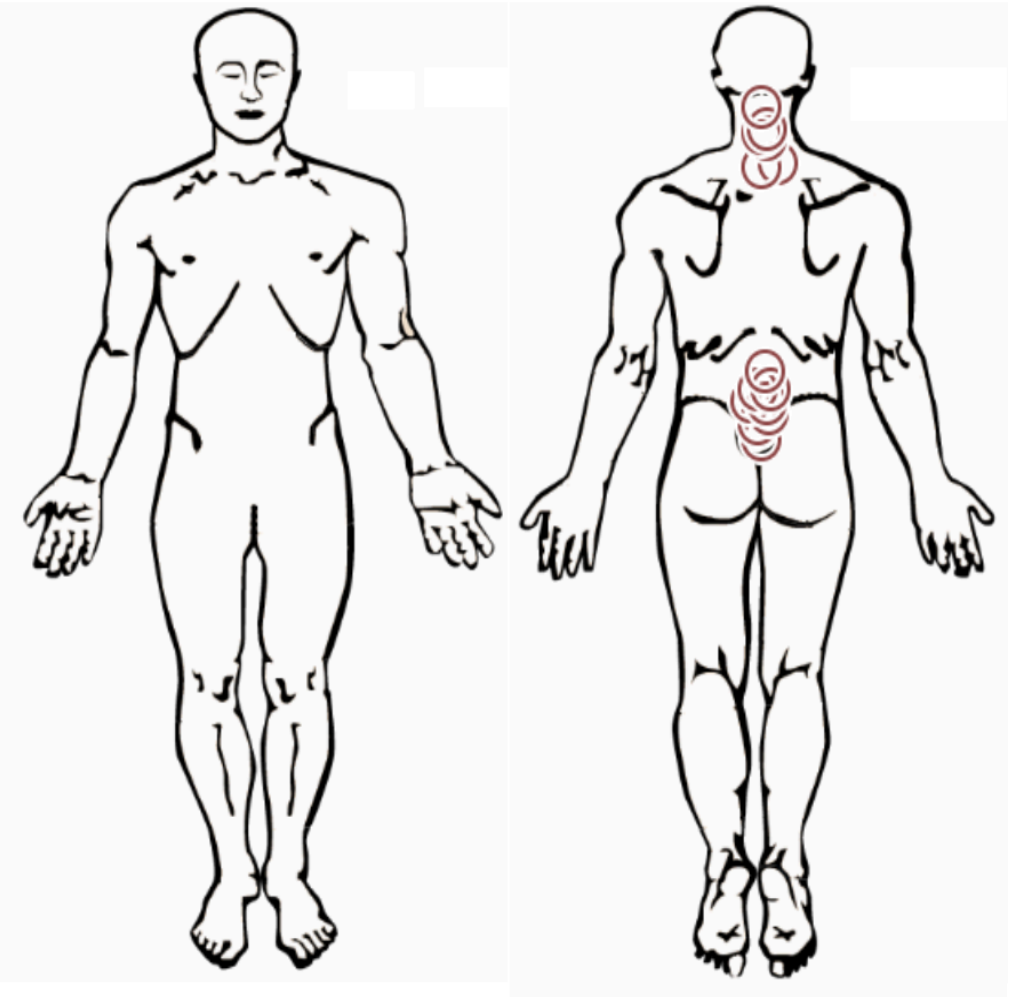

- **Ache / Dull**
- **Sharp / Stabbing**
- **Numb / Tingling**
- **Pins & Needles**
- **Burning**
- **Throbbing**
- **Cramping**
- **Radiating**
- **Other Pains**

ELITE RADIOLOGY OF GEORGIA

Image is Everything

You are scheduled at:

- ❒ **4800 Ashford Dunwoody Rd., Ste 140**
  Atlanta, GA 30338
  Tel: 404-419-2058
  Fax: 404-381-8263
  ★ *1.5T MRI & X-Ray*
- ❒ **1458 Church St., Ste D**
  Decatur, GA 30033
  Tel: 404-937-2965
  Fax: 404-745-0354
  ★ *Upright Open MRI & X-Ray*
- ❒ **790 Church St., Ste 105**
  Marietta, GA 30060
  Tel: 470-462-0134
  Fax: 470-462-2444
  ★ *1.5T MRI & X-Ray*
- ❒ **1040 Eagles Landing Parkway, Ste 102**
  Stockbridge, GA 30281
  Tel: 770-462-8809
  Fax: 770-988-7898
  ★ *3T High-Field MRI & X-Ray*
- ❒ **3547 Peachtree Industrial Blvd., Ste 4**
  Duluth, GA 30096
  Tel: 770-299-1332
  Fax: 770-741-0097
  ★ *1.5T MRI & X-Ray*
- ❒ **939 Bob Arnold Blvd. Ste C**
  Lithia Springs, GA 30122
  Tel: 770-462-0767
  Fax: 770-450-0702
  ★ *3T MRI & X-Ray*

❒ Health ❒ WC ☑ Auto ❒ Other: _____

Appointment Date: _____ Time: _____

Patient Name: Imoni Chapman DOB: 05/03/2001

Patient Phone: (678) 983-5216

Insurance Provider: _____ Group #: _____

Insurance Tel: _____ Claim #: _____

Referring Physician: Dr. Michael Gellman Physician Tel: 678-505-0000

Physician Signature: Michael Gellman Date: 06/26/2024

Clinic Name: Peachtree Wellness Chiropractic Physician Fax: 470-823-9759

Injury Date: 06/06/2024 Attorney: Kim Law

Diagnosis: _____

MRI

- ❒ Brain ❒ w/ SWI ❒ w/ DTI
- ❒ IAC's
- ❒ Pituitary
- ❒ Orbits
- ☑ Cervical Spine
- ❒ Thoracic Spine
- ☑ Lumbar Spine
- ❒ Shoulder ❒ L ❒ R
- ❒ Knee ❒ L ❒ R

❒ ***3D Rendering if positive***

- ❒ Soft Tissue Neck
- ❒ Brachial Plexus
- ❒ Chest
- ❒ Abdomen
- ❒ Pelvis
- ❒ Elbow ❒ L ❒ R
- ❒ Wrist ❒ L ❒ R
- ❒ Hand ❒ L ❒ R
- ❒ Hip ❒ L ❒ R
- ❒ Ankle ❒ L ❒ R
- ❒ Foot ❒ L ❒ R
- ❒ Other _____

CONTRAST

❒ With ☑ Without ❒ With & Without

GENERAL RADIOLOGY

- ❒ Skull
- ❒ Facial
- ❒ Orbits
- ❒ Sinus
- ❒ Nasal
- ❒ Soft Tissue Neck
- ❒ Chest (CXR)
- ❒ Abdominal Series
- ❒ KUB
- ❒ Pelvis
- ❒ SI Joints
- ❒ Sacrum / Coccyx
- ❒ C-Spine
- ❒ T-Spine
- ❒ L-Spine
- ❒ Bone Age
- ❒ Other _____

- ❒ TMJ ❒ L ❒ R
- ❒ Clavicle ❒ L ❒ R
- ❒ Shoulder ❒ L ❒ R
- ❒ Humerus ❒ L ❒ R
- ❒ Elbow ❒ L ❒ R
- ❒ Forearm ❒ L ❒ R
- ❒ Wrist ❒ L ❒ R
- ❒ Hand ❒ L ❒ R
- ❒ Finger ❒ L ❒ R
- ❒ Ribs ❒ L ❒ R
- ❒ Hip ❒ L ❒ R
- ❒ Femur ❒ L ❒ R
- ❒ Knee ❒ L ❒ R
- ❒ Tibia ❒ L ❒ R
- ❒ Fibula ❒ L ❒ R
- ❒ Ankle ❒ L ❒ R
- ❒ Foot ❒ L ❒ R
- ❒ Calcaneus ❒ L ❒ R
- ❒ Toes ❒ L ❒ R

MRA

- ❒ Brain (COW) w/o Contrast
- ❒ Carotid w/o Contrast
- ❒ Other _____

UPRIGHT OPEN MRI

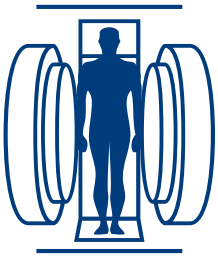

Upright MRI Protocol

With Flexion/Extension?
❒ Yes ❒ No

With Alar Protocol?
❒ Yes ❒ No

With Contrast?
❒ Yes ❒ No

- ❒ Brain
- ❒ Cervical ❒ Seated ❒ Standing
- ❒ Thoracic ❒ Seated ❒ Standing
- ❒ Lumbar ❒ Seated ❒ Standing
- ❒ Shoulder ❒ L ❒ R
- ❒ Hip ❒ L ❒ R
- ❒ Knee ❒ L ❒ R
- ❒ Other Region: _____

TRAUMA PROTOCOLS

- ❒ Brain ❒ w/ SWI ❒ w/ DTI
- ❒ C-Spine w/ Flexion/Extension
- ❒ C-Spine w/ Alar
- ❒ Other _____

Additional Notes: _____

ADVANCED IMAGING CENTERS

Phone: 404-596-7449
Fax: 404-541-4777
Email: info@advancedimagingcenters.com
Website: www.advancedimagingcenters.com

- ☐ Buckhead/Midtown
- ☐ Canton
- ☐ Decatur
- ☐ Fayetteville
- ☐ Kennestone
- ☐ Marietta
- ☐ Newnan
- ☐ Norcross
- ☐ Peachtree City
- ☐ Statesboro

PHYSICIAN ORDER FORM

PATIENT INFORMATION

Patient Name: Imoni Chapman

Patient Address:

Patient Phone: (678) 983-5216

Patient Email:

DOB: 05/03/2001

Gender: Female

Height: _____ Weight: _____

PHYSICIAN INFORMATION

Referring Physician: Dr. Michael Gellman

Referring Clinic: Iceberg Injury

Diagnosis: Sprain in the Ligament of Cervical and Lumbar spine

Phone: 647-505-0000

Email:

Fax: 470-823-9759

MRI

HEAD & NECK

- ☐ Brain
- ☐ Neck Soft Tissue
- ☐ TMJ
- ☐ Face
- ☐ IAC / Pituitary
- ☐ Orbits

BODY

- ☐ Abdomen
- ☐ Abdomen / MRCP
- ☐ Adbomen / Kidneys
- ☐ Abdomen / Adrenal Glands
- ☐ Abdomen / Liver
- ☐ Brachial Plexus
- ☐ Pelvis Soft-Tissue
- ☐ Bony Pelvis
- ☐ Sacrum / Coccyx
- ☐ Chest

MUSCULOSKELETAL

☐ Ankle	○ L	○ R
☐ Clavicle	○ L	○ R
☐ Elbow	○ L	○ R
☐ Femur	○ L	○ R
☐ Finger	○ L	○ R
☐ Foot	○ L	○ R
☐ Forearm	○ L	○ R
☐ Hand	○ L	○ R
☐ Heel	○ L	○ R
☐ Hip	○ L	○ R
☐ Humerus	○ L	○ R
☐ Knee	○ L	○ R
☐ Shoulder	○ L	○ R
☐ Tibia / Fibula	○ L	○ R
☐ Toes	○ L	○ R
☐ Wrist	○ L	○ R
☐ Other: _____	○ L	○ R

CONTRAST

☐ w ☑ w/o ☐ w & w/o

SPINE

- ☑ C-Spine
- ☐ T-Spine
- ☑ L-Spine

MRA

- ☐ Brain / Head / Circle of Willis
- ☐ Neck / Carotid

ATTORNEY INFORMATION

ICD-10 Code/Diagnosis:

Attorney Name: Kim Law

Attorney Number: (404) 587-8946

Date of injury: 06/06/2024

- ☐ Work Comp
- ☑ MVA
- ☐ Slip and Fall

PHYSICIAN'S NOTES *Applicable Patient History Description*

Specify exam if not listed: _____

Additional Notes: _____

Physician Signature: _____

Date: 7/29/2024

ADVANCED IMAGING CENTERS

PATIENT:	CHAPMAN, IMONI
DOB:	5/3/2001
FILE #:	OPI3333341
PHYSICIAN:	GELLMAN, MICHAEL DR.
EXAMS:	MRI SPINE LUMBAR W/O CONTRAST
DATE:	8/10/2024 1:45:00 PM

MRI OF THE LUMBAR SPINE:

HISTORY: Patient with history of motor vehicle collision dated 6/6/2024 with low back pain.

TECHNIQUE: Multisequence T1 and T2 weighted images were obtained.

FINDINGS: The conus medullaris appears normal. The lordotic curvature of the lumbar spine is preserved. No evidence for abnormal solid or cystic lesions is identified. No prevertebral or paravertebral masses or fluid collections are seen and there is no evidence for abnormal marrow replacing lesion.

Segmental analysis of the lumbar spine is as follows:

At L1-2, there is no evidence for disc herniation, canal stenosis or neural foraminal stenosis.

At L2-3, there is no evidence for disc herniation, canal stenosis or neural foraminal stenosis.

At L3-4, there is no evidence for disc herniation, canal stenosis or neural foraminal stenosis.

At L4-5, there is bulging of the disc. This results in an anterior impression on the thecal sac. There are no osteophytes. There is no central canal stenosis or foraminal stenosis.

At L5-S1, there is bulging of the disc. This results in an anterior impression on the thecal sac. There are no osteophytes. There is no central canal stenosis or foraminal stenosis.

IMPRESSION:
1. At L4-5, there is bulging of the disc. This results in an anterior impression on the thecal sac.
2. At L5-S1, there is bulging of the disc. This results in an anterior impression on the thecal sac.
3. There are findings on this examination which may be related to the patient's symptoms and the event in the patient's history. This needs to be determined clinically, and therefore clinical correlation is recommended. Specifically, the level of L4-L5 and L5-S1.

The definitions in this report, including definitions of disc bulge, disc herniation, protrusion, and extrusion, are from the following peer reviewed journal: Lumbar Disc Nomenclature V2.0, Recommendations of the Combined Task Forces of the North American Spine Society, the American Society of Spine Radiology and the American Society of Neuroradiology, The Spine Journal 14 (2014) 2525 2545. References to causation and permanency follow guidelines established by the American Medical Association. Note that a normal MRI does not exclude certain pathologies, including pathologies involving the nerves and facet joints. A normal MRI should not supersede abnormalities detected with physical exam. Disc herniations are contained herniated discs unless specifically identified as uncontained.

Thank you for your kind referral.

JONATHAN C. EUGENIO, M.D.
ELITERAD RADIOLOGY GROUP
CERTIFIED, AMERICAN BOARD OF RADIOLOGY
AMERICAN SOCIETY OF NEURORADIOLOGY

JCE/JN

ADVANCED IMAGING CENTERS

PATIENT:	CHAPMAN, IMONI
DOB:	5/3/2001
FILE #:	OPI3333340
PHYSICIAN:	GELLMAN, MICHAEL DR.
EXAMS:	MRI SPINE CERVICAL W/O CONTRAST
DATE:	8/10/2024 1:26:28 PM

MRI OF THE CERVICAL SPINE:

HISTORY: MVC dated 06/06/2024 with neck pain.

TECHNIQUE: Multisequence T1 and T2 weighted images were obtained.

FINDINGS: The posterior fossa structures are normal. The cervical cord structures are normal. There is loss of the normal lordotic curvature of the cervical spine. In the correct clinical setting, this may reflect injury. Clinical correlation is recommended. No prevertebral or paravertebral masses or fluid collections are identified. Segmental analysis of the cervical spine is as follows:

At C2-3, there is no evidence for disc herniation, canal stenosis or neural foraminal stenosis.

At C3-4, there is bulging of the disc. This results in an anterior impression on the thecal sac. There is no central canal stenosis or foraminal stenosis.

At C4-5, there is bulging of the disc. This results in an anterior impression on the thecal sac. There is no central canal stenosis or foraminal stenosis.

At C5-6, there is bulging of the disc. This results in an anterior impression on the thecal sac. There is no central canal stenosis or foraminal stenosis.

At C6-7, there is no evidence for disc herniation, canal stenosis or neural foraminal stenosis.

At C7-T1, there is no evidence for disc herniation, canal stenosis or neural foraminal stenosis.

IMPRESSION:
1. There is loss of the normal lordotic curvature of the cervical spine. In the correct clinical setting, this may reflect injury. Clinical correlation is recommended.
2. At C3-4, there is bulging of the disc. This results in an anterior impression on the thecal sac.
3. At C4-5, there is bulging of the disc. This results in an anterior impression on the thecal sac.
4. At C5-6, there is bulging of the disc. This results in an anterior impression on the thecal sac.

The definitions in this report, including definitions of disc bulge, herniation, protrusion, and extrusion, are from the following peer reviewed journal: Disc Nomenclature V2.0, Recommendations of the Combined Task Forces of the North American Spine Society, the American Society of Spine Radiology and the American Society of Neuroradiology, The Spine Journal 14 (2014) 2525-2545. References to causation and permanency follow guidelines established by the American Medical Association. Note that a normal MRI does not exclude certain pathologies, including pathologies involving the nerves and facet joints. A normal MRI should not supersede abnormalities detected with physical exam. Disc herniations are contained herniated discs unless specifically identified as uncontained.

Thank you for your kind referral.

JONATHAN C. EUGENIO, M.D.
ELITERAD RADIOLOGY GROUP
CERTIFIED, AMERICAN BOARD OF RADIOLOGY
AMERICAN SOCIETY OF NEURORADIOLOGY

JCE/TB

ADVANCED IMAGING CENTERS

PATIENT:	CHAPMAN, IMONI
DOB:	5/3/2001
FILE #:	OPI3333340
PHYSICIAN:	GELLMAN, MICHAEL DR.
EXAMS:	MRI SPINE CERVICAL W/O CONTRAST
DATE:	8/10/2024 1:26:28 PM

MRI OF THE CERVICAL SPINE:

HISTORY: MVC dated 06/06/2024 with neck pain.

TECHNIQUE: Multisequence T1 and T2 weighted images were obtained.

FINDINGS: The posterior fossa structures are normal. The cervical cord structures are normal. There is loss of the normal lordotic curvature of the cervical spine. In the correct clinical setting, this may reflect injury. Clinical correlation is recommended. No prevertebral or paravertebral masses or fluid collections are identified. Segmental analysis of the cervical spine is as follows:

At C2-3, there is no evidence for disc herniation, canal stenosis or neural foraminal stenosis.

At C3-4, there is bulging of the disc. This results in an anterior impression on the thecal sac. There is no central canal stenosis or foraminal stenosis.

At C4-5, there is bulging of the disc. This results in an anterior impression on the thecal sac. There is no central canal stenosis or foraminal stenosis.

At C5-6, there is bulging of the disc. This results in an anterior impression on the thecal sac. There is no central canal stenosis or foraminal stenosis.

At C6-7, there is no evidence for disc herniation, canal stenosis or neural foraminal stenosis.

At C7-T1, there is no evidence for disc herniation, canal stenosis or neural foraminal stenosis.

IMPRESSION:
1. There is loss of the normal lordotic curvature of the cervical spine. In the correct clinical setting, this may reflect injury. Clinical correlation is recommended.
2. At C3-4, there is bulging of the disc. This results in an anterior impression on the thecal sac.
3. At C4-5, there is bulging of the disc. This results in an anterior impression on the thecal sac.
4. At C5-6, there is bulging of the disc. This results in an anterior impression on the thecal sac.

The definitions in this report, including definitions of disc bulge, herniation, protrusion, and extrusion, are from the following peer reviewed journal: Disc Nomenclature V2.0, Recommendations of the Combined Task Forces of the North American Spine Society, the American Society of Spine Radiology and the American Society of Neuroradiology, The Spine Journal 14 (2014) 2525-2545. References to causation and permanency follow guidelines established by the American Medical Association. Note that a normal MRI does not exclude certain pathologies, including pathologies involving the nerves and facet joints. A normal MRI should not supersede abnormalities detected with physical exam. Disc herniations are contained herniated discs unless specifically identified as uncontained.

Thank you for your kind referral.

JONATHAN C. EUGENIO, M.D.
ELITERAD RADIOLOGY GROUP
CERTIFIED, AMERICAN BOARD OF RADIOLOGY
AMERICAN SOCIETY OF NEURORADIOLOGY

JCE/TB

ADVANCED IMAGING CENTERS

PATIENT:	CHAPMAN, IMONI
DOB:	5/3/2001
FILE #:	OPI3333341
PHYSICIAN:	GELLMAN, MICHAEL DR.
EXAMS:	MRI SPINE LUMBAR W/O CONTRAST
DATE:	8/10/2024 1:45:00 PM

MRI OF THE LUMBAR SPINE:

HISTORY: Patient with history of motor vehicle collision dated 6/6/2024 with low back pain.

TECHNIQUE: Multisequence T1 and T2 weighted images were obtained.

FINDINGS: The conus medullaris appears normal. The lordotic curvature of the lumbar spine is preserved. No evidence for abnormal solid or cystic lesions is identified. No prevertebral or paravertebral masses or fluid collections are seen and there is no evidence for abnormal marrow replacing lesion.

Segmental analysis of the lumbar spine is as follows:

At L1-2, there is no evidence for disc herniation, canal stenosis or neural foraminal stenosis.

At L2-3, there is no evidence for disc herniation, canal stenosis or neural foraminal stenosis.

At L3-4, there is no evidence for disc herniation, canal stenosis or neural foraminal stenosis.

At L4-5, there is bulging of the disc. This results in an anterior impression on the thecal sac. There are no osteophytes. There is no central canal stenosis or foraminal stenosis.

At L5-S1, there is bulging of the disc. This results in an anterior impression on the thecal sac. There are no osteophytes. There is no central canal stenosis or foraminal stenosis.

IMPRESSION:
1. At L4-5, there is bulging of the disc. This results in an anterior impression on the thecal sac.
2. At L5-S1, there is bulging of the disc. This results in an anterior impression on the thecal sac.
3. There are findings on this examination which may be related to the patient's symptoms and the event in the patient's history. This needs to be determined clinically, and therefore clinical correlation is recommended. Specifically, the level of L4-L5 and L5-S1.

The definitions in this report, including definitions of disc bulge, disc herniation, protrusion, and extrusion, are from the following peer reviewed journal: Lumbar Disc Nomenclature V2.0, Recommendations of the Combined Task Forces of the North American Spine Society, the American Society of Spine Radiology and the American Society of Neuroradiology, The Spine Journal 14 (2014) 2525 2545. References to causation and permanency follow guidelines established by the American Medical Association. Note that a normal MRI does not exclude certain pathologies, including pathologies involving the nerves and facet joints. A normal MRI should not supersede abnormalities detected with physical exam. Disc herniations are contained herniated discs unless specifically identified as uncontained.

Thank you for your kind referral.

JONATHAN C. EUGENIO, M.D.
ELITERAD RADIOLOGY GROUP
CERTIFIED, AMERICAN BOARD OF RADIOLOGY
AMERICAN SOCIETY OF NEURORADIOLOGY

JCE/JN

Acute Spine & Joint

REQUEST FOR APPOINTMENT

Patient's Name:	Imoni Chapman				
Home Address:			City:		Zip
Phone:	(678) 983-5216		Alternate Phone:		
Date of Birth:	05/03/2001		SSN:		
Gender:	Male ○ Female ◉ Other		Preferred Language: English ○ Spanish ○ Other		
Reason for Visit:	New Patient MVA ○	New Patient Accepted Work Comp ○	New Patient Controverted Work Comp ○	New Patient Insurance ○	Independent Medical Exam ○	Other ◉
Type of Injury:	MVA ◉	Workers Comp ○	Slip & Fall ○	Self-pay ○	Insurance ○	Other ○
Injured Body Part(s):	Sprain in the ligament of Cervical and Lumbar spine				
Has patient had Previous Treatment? Yes ◉ No ○			If so, where:		
Has patient had Previous MRIs? Yes ◉ No ○			If so, where: AIC		

If using health insurance: please provide front and back of card

MVA using health insurance: MUST provide Medpay declarations page prior to filing insurance.

Medpay – Auto Coverage, Slip & Fall, etc.			
Company Name:	Name of Insured:		Claim ID:
Claims Address:		Adjuster Name:	
Adjuster Email:	Adjuster Phone:	Adjuster Fax:	
Insurance Carrier			
Primary Insurance:	Policy Holder Name:		Policy Holder's Date of Birth:
Relationship to Policy Holder:	Member ID:	Group Number:	Specialist Co-Pay:

Patient's Attorney:		Firm:	The Kim Law
Assistant/Paralegal:		Phone:	(404) 587-8946
Email:		Fax:	

Questions: 770-256-3691 Please return information to: Fax: 877-442-2883 or Yari@tekmanageco.com
Please include signed lien if applicable.

PHYSICIAN PRACTICE LIEN AGREEMENT

Today's Date: _____

This Physician Practice Lien Agreement (the "Agreement") is hereby entered into by and among:

_____ ("Patient"), Patient's Name

_____ ("Attorney"),

and Acute Spine & Joint, LLC ("Provider").

Patient acknowledges that, in accordance with the Health Information Portability and Accountability Act of 1996 ("HIPAA"), Patient's medical information relating to the Legal Action may be shared to manage and expedite Patient's medical treatment. Patient authorizes Provider to release any information needed by Attorney to pursue the Legal Action, including without limitation information (including billing information) regarding the examination, treatment, procedures and services rendered by Provider. Patient authorizes Attorney to secure, release, and disclose such medical treatment information with individuals and entities as deemed necessary to pursue the Legal Action.

Patient further agrees that examinations, diagnoses, medical treatments, films and reports can be shared with necessary parties involved in the Legal Action. Attorney acknowledges that Attorney has obtained a Release of Medical Information from Patient for purposes of communications regarding Patient's medical information. Patient expressly authorizes Attorney to keep Provider advised of the progress of the Legal Action at reasonable intervals.

Patient hereby grants to Provider a Lien on the proceeds of any settlement, judgment or verdict in the Legal Action which may be paid to Patient or to Attorney. Patient hereby notifies Attorney that Patient is giving Provider a lien on these benefits or settlement proceeds, and Patient hereby authorizes and directs Attorney to withhold such funds from any settlement, verdict or judgment that is rendered in the Legal Action and pay Provider directly from any such proceeds any sums due for medical services rendered to Patient. This lien is irrevocable and can only be satisfied by full payment of all sums due for medical services rendered, unless Provider expressly agrees otherwise in writing.

Patient understands that any settlement, verdict or judgment proceeds cannot be disbursed to Patient without first satisfying this lien.

Should a dispute arise regarding payment of Provider's charges, Patient authorizes and directs Attorney to hold in escrow all monies sufficient to satisfy this lien until the dispute can be resolved. Patient and Attorney acknowledge that it would be a violation of Attorney's ethical duties to disburse the disputed funds prior to resolution of the lien dispute.

Patient understands and agrees that even though this lien has been given, Patient remains personally responsible for payment in full of Provider's fees for all services rendered, including without limitation fees for services provided at Provider's office locations (e.g., exams and office visits, x-rays, injections, MRIs, DME, supplies, medicine through Comprehensive Rx). Patient is solely responsible for making appropriate arrangements for payment of such fees, including but not limited to insurance benefits. Patient acknowledges that this obligation to pay Provider's fees is not dependent on the outcome of Patient's court case. Provider and Patient agree that in the event it is necessary to enforce this Agreement in a court of law, then in addition to all damages and costs, the prevailing party shall be entitled to reasonable attorney's fees in the amount of 20% of the amount at issue.

Provider hereby agrees to await Patient's payment of Provider's fees until the Legal Action is resolved by settlement, judgment or verdict, except to the extent that payment is available from Patient's medical insurance. Patient and Attorney hereby expressly acknowledge the validity and enforceability of Provider's lien as of the date Provider's treatment of Patient commences and expressly agree to be bound by the terms of this Agreement. Patient and Attorney expressly acknowledge that this Agreement constitutes actual notice of Provider's lien pursuant to OCGA §44-14- 471(b), and Patient waives the right to assert any defense to the validity and enforceability of Provider's lien based on Provider's failure to perfect the lien in accordance with OCGA §44-14-471(a). Patient hereby directs and authorizes Attorney to provide actual notice of Provider's lien to all parties involved in the Legal Action in accordance with the requirements of OCGA §44-14-471(b), and Attorney agrees to be responsible for providing such notice. The parties agree that a photocopy of this Agreement shall be considered as valid as the original.

If Patient should retain new legal counsel, Attorney and Patient agree to notify Provider immediately upon such change. Patient shall direct such new legal counsel to execute another copy of this Agreement and deliver same to Provider.

This Agreement cannot be modified, amended or revoked by any party without the express written consent of all parties.

If the net recovery is less than the outstanding charges owed to all health care providers covered by letters of protection or lien rights, net settlement proceeds will be distributed on a pro rata basis or as required by legal priority under Georgia or other applicable law.

ACKNOWLEDGEMENT BY PATIENT:

I acknowledge that this Agreement must be signed by myself and by my attorney before any medical services will be provided to me by Provider. I have been advised that if my attorney does not wish to cooperate in protecting Provider's interest, Provider will await payment and may declare the entire balance due and payable.

Patient's Signature Name: _____

Patient's Address: _____

Date: _____

Acute Spine & Joint, LLC: _____

Date: _____

PATIENT'S ATTORNEY ACKNOWLEDGEMENT:

Attorney - Please sign, date and return a copy of this Agreement to Acute Spine & Joint, LLC and keep a copy for your records.

Acknowledged and Accepted:

Attorney Firm: _____

Attorney Name: _____

Attorney Signature: _____

Attorney Address: _____

Date: _____

ATLANTA
REGENERATIVE
MEDICINE
INSTITUTE

Carroll D. Cooper, MD
Board Certified Interventional Pain Management Board
Certified Physical Medicine & Rehabilitation
Pickens A. Patterson, III, MD
Board Certified Anesthesiologist & Pain Management
Ara Chitchyan, MD
Board Certified Physical Medicine & Rehabilitation

5243 Snapfinger Woods Dr ♦ Suite 101 ♦ Stonecrest, GA 30035
251 Medical Way ♦ Suite B ♦ Riverdale, GA 30274
3656 Highlands Parkway, SE♦ Smyrna, GA 30082
3048 Napier Ave ♦ Macon, GA 31204

Office: (404) 355-2728 Fax: (404) 662-2344

REFERRAL FORM

Date 09/23/2024

Patient Name Imoni Chapman

Diagnosis Sprain in the Ligament of Cervical and Lumbar spine

Patient Phone Number (678) 983-5216

✓	**Personal Injury**		**Prolo Therapy**
	EMG/NCV Study		**Ultrasound Guided Injections**
	Epidural Steroid Injection		**Platelet Rich Plasma Injections**
	Evaluate & Treat		**Stem Cell Injections**
	Impairment Ratings		**Spine Injections**
	Independent Medical Exam		**Disability Evaluation**

Attorney The Kim Law

Requesting Physician Dr. Michael Gellman

Requesting Physician Phone/Fax Number 678-505-0000